

# Suppression of Wnt Expression by Increasing PI3K in Rats Cervical Carcinoma by Andaliman (Zanthoxylum acanthopodium)

*by* Turnitin®

---

**Submission date:** 02-Jan-2024 09:58PM (UTC+0700)

**Submission ID:** 2266169058

**File name:** Cervical\_Carcinoma\_by\_Andaliman\_Zanthoxylum\_acanthopodium.docx (1.06M)

**Word count:** 3044

**Character count:** 16611

## Research Article

# Suppression of Wnt Expression by Increasing PI3K in Rats Cervical Carcinoma by Andaliman (*Zanthoxylum acanthopodium*)

17

### Abstract

**Background and Objective:** Cervical cancer is the leading cause of death for women in the world and Indonesia. This disease originates from a malignant tumour of squamous epithelial cells caused by infection with the Human Papilloma Virus (HPV). Antioxidants can reduce oxidative stress in and there are plants from Indonesia that have high antioxidants, namely andaliman (*Zanthoxylum acanthopodium*). This study aimed to analyze the role of andaliman on PI3K and Wnt signalling in cervical cancer histology. **Materials and Methods:** The study includes 5 treatments. The control group (K-), rats cancer model (K+), rats cancer model+the dose is 100 mg/b.wt. of ZAM (P<sub>1</sub>), rats cancer model+the dose is 200 mg/b.wt. of ZAM (P<sub>2</sub>) and rats cancer model+the dosage is 400 mg/b.wt. ZAM (P<sub>3</sub>). On the 30th day after ZAM administration, the rats were dissected for the paraffin block and Wnt and PI3K immunohistochemical staining was prepared. **Results:** There was a significant difference between all groups ( $p < 0.001$ ) in Wnt and PI3K expression. The real role of ZAM in cervical cancer tissue was seen at the highest ZAM dose (P<sub>3</sub>). Irregular mucosal folds and stretched interstitial connective tissue in the K+ group can return to regularity and improve at the P<sub>3</sub> dose. The administration of ZAM showed a significant difference in cervical tissue after benzopyrene injection. **Conclusion:** Andaliman (*Zanthoxylum acanthopodium*) extract increases PI3K expression through suppression of Wnt expression. It can be developed therapy molecularly to prevent cell growth into cancer.

**Key words:** Andaliman, carcinoma cervical, herbal plant, immunohistochemistry, PI3K, Wnt, *Zanthoxylum acanthopodium*

Cervical cancer is one of the leading causes of death for women in the world. Cervical cancer ranks highest in developing countries and ranks 10th in developed countries or ranks 5th globally<sup>1</sup>. In Indonesia, the global cancer survey shows that cervical cancer is the second-highest incidence and mortality rate among women with a mortality rate of 6.9 per 100,000<sup>2,3</sup>. Cervical cancer is a malignant tumour originating from squamous epithelial cells. Regardless of age and background, every woman is at risk of developing cancer caused by infection with the Human Papilloma Virus (HPV)<sup>3</sup>.

Pathogen signalling frequently activated in cancer is the Phosphatidylinositol-3 Kinase (PI3K) pathway. This route is an important target for the development and of anticancer drugs<sup>4</sup>. PI3K is also called a lipid kinase which plays a central role in cell cycle regulation, apoptosis, DNA repair, ageing, angiogenesis, cellular metabolism and motility<sup>4,5</sup>. PI3K represents a family of lipid kinases located upstream of the intracellular signalling network and is interconnected key cellular processes such as proliferation, differentiation, senescence, motility and survival are regulated by RTK and G-Protein-Coupled Receptors (GPCRs) through the production of phosphorylated lipids to the cytoplasm<sup>5</sup>. Antioxidant activity significantly scavenges free radicals and antioxidants can inhibit A $\beta$  neurotoxicity by decreasing intracellular Reactive Oxygen Species (ROS) via the PI3K/Akt signalling pathway<sup>6</sup>.

One of the signaling pathways that regulate cell proliferation and differentiation is Wnt<sup>7</sup>. This pathway plays a role in the growth and development of malignant tumors including cervical cancer<sup>7,8</sup>. The Wnt signalling pathway consists of various signalling molecules, ligands and receptors such as Wnt protein and catenin<sup>8</sup>. This pathway consists mainly of three pathways: The classical Wnt pathway, the Wnt/Ca<sup>2+</sup> pathway and the Planar Cell Polarity (PCP) pathway<sup>7</sup>. Tumour cells that develop into malignant tumours can be metabolically reprogrammed via Wnt signaling<sup>8</sup>. In tumour cells, especially cancer, the amount of oxygen free radicals in tumour cells is increased compared to normal cells and increased ROS stimulates tumour cell proliferation<sup>9,10</sup>. Here, Wnt plays a role in tumour metabolic reprogramming by encouraging nutrients such as antioxidants to be more "effective" to inhibit the robust metabolism of tumour cells<sup>10</sup>.

Antioxidants can reduce oxidative stress in cells<sup>11</sup>. Polymorphisms in this enzyme are thought to be related to DNA damage<sup>7,11</sup>. One of the plants from Indonesia that have high antioxidants is Andaliman (*Zanthoxylum acanthopodium*). This herb has been used by the people of

Indonesia (Batak tribe, North Sumatera province) for flavouring, health and anti-inflammatory properties<sup>12,13</sup>. Andaliman fruit extracts showed antioxidant activity<sup>14</sup>. Nano-sized Andaliman can also reduce MDA levels, increase HSP-70 and improve liver and placenta in Pre-Eclampsia (PE)<sup>15-18</sup>. Molecularly Andaliman can inhibit apoptosis via cytochrome c and FasL in the placenta<sup>19</sup>, affect the performance of FGFb in diabetic burns<sup>20</sup> and the Hes1 and notch1 genes in human trophoblasts<sup>21</sup>.

This study aimed to analyze the role of Andaliman on PI3K and Wnt signalling in cervical cancer histology.

## MATERIALS AND METHODS

**Study area:** The research project was conducted from June, 2020-August, 2021. The research was carried out in the Animal House, the Physiology Laboratory and the Anatomical Pathology Laboratory of the Department of Biology, Faculty of Mathematics and Natural Sciences, University of Sumatera Utara and Perform medicine, Universitas Sumatera Utara.

**Preparation of *Zanthoxylum acanthopodium* extract methanol (ZAM):** Andaliman fruits come from Berastagi in northern Sumatra. Removed the dirt or dust sticking to the fruit and then it is dried in a fine blender without branches at room temperature for 7 days. The Andaliman fruit extract is prepared in three steps: Firstly, The raw material is dried: It is washed and drained and then mashed by a mixer. Secondly, Preparation of ZAM: Andaliman fruit powder soaked in 96% methanol (1 night) and the result of maceration and penetration of plant matter until a clear liquid is obtained. The result of diafiltration was concentrated with an evaporator until the obtained extract was concentrated. Thirdly, Preparation of drug suspension: The dose is 100, 200 and 400 mg/b.wt. during 30 days of administration.

**Animal handling:** Thirty-six female Wistar rats from Animal House, The Biology Laboratory, University of Sumatera Utara (USU) were used in this study. Before the study, the rats were allowed to adapt to the laboratory conditions for 1 month and the rats were given standardized rat pellets and plenty of water. For an animal cancer model, rats cancer by inducing benzopyrene 50 mg/b.wt. in the cervix and allowed cancer to grow only after three months.

**Study design:** The study includes 5 treatments. The K- group is the control group, the K+ group is the rat's cancer model, the P<sub>1</sub> group is the rat's cancer model+the dose is 100 mg/b.wt. of ZAM, the P<sub>2</sub> group is the rat's cancer model+

the dose is 200 mg/b.wt. of ZAM and the P<sub>3</sub> group is the rat's cancer Model+the dosage is 400 mg/b.wt. ZAM, administered for 30 days. On the 30th day after ZAM administration, the rats were dissected and the cervix was taken out for the cervical paraffin block and Wnt and PI3K immunohistochemical staining were prepared.

**Immunohistochemistry staining of PI3K and Wnt:** Cervical tissue preparations were stained with Hematoxylin–Eosin (HE). Cervical cancer tissue in paraffin blocks was cut using a microtome and mounted on poly-lysine-coated glass slides and dried (1 night at room temperature). Deparaffinization with xylene for 5 min (twice) then rehydrated by lowering the concentration ethanol decreased (100% ethanol, 90% ethanol, 80% ethanol and 70% ethanol) twice (5 min). Cervical cancer tissue was rehydrated and stored in Phosphate-Buffered Saline (PBS). Primary antibodies,  $\beta$ -catenin (sc-7199) as well as rabbit ABC staining system (sc-2018), were obtained from Santa Cruz Biotechnology (Santa Cruz, CA, USA). PI3K P110a (C73F8) antibodies were purchased from Cell Signaling Technology (Danvers, MA, USA). Antigen retrieval using 100 mM sodium citrate buffer (pH 6.0) for 10 min in a microwave oven. Then the slide is immersed in hydrogen peroxide (0.3%) at PBS (V/V) for 30 min to extinguish the endogenous peroxidase activity. Slides were blocked with 10% skim milk (w/v) in PBS (45 min), slides were incubated with primary antibody diluted in PBS at 40°C (overnight). Then, the slides were incubated with Envision™. Conjugated secondary antibody peroxidase (DAKO, Denmark) for 1 hr and p peroxidase, 0.1% diaminobenzidine tetrahydrochloride (DAB) solution for 10 min. The stained tissue is observed under a light microscope<sup>22</sup>.

**Data analysis:** Research data using SPSS software version 22 using the Kruskal-Wallis test and then proceed with the Mann-Whitney test.

## RESULTS

**Histopathological changes of cervical cancer:** Histology of cervical tissue induced by benzopyrene in several treatments with Haematoxylin Eosin (HE) staining is known that the K- group has regular histology compared to the K+ group (cervical cancer) cervical tissue consists of squamous epithelium (squamous stratified epithelium) (Fig. 1a). The cervical mucosal layer consists of glands that produce mucus. Mucous fold structure in the K+ group spreads to the interstitial connective tissue (Fig. 1b). In addition, the cell nucleus has also left the cell. However, with the administration of ZAM, at a dose of 100 mg kg<sup>-1</sup> b.wt. (Fig. 1c), a dose of

200 mg kg<sup>-1</sup> b.wt. (Fig. 1d) and a dose of 400 mg kg<sup>-1</sup> b.wt. (Fig. 1e), tissue repair began to return to normal as in the control group. The real role of ZAM in cervical cancer tissue was seen at the highest ZAM dose (Fig. 1e). Irregular mucosal folds and stretched interstitial connective tissue in the K+ group (Fig. 1b) can return to regularity and improve at the P<sub>3</sub> dose (Fig. 1e).

**Histology of cervical cells on PI3K expression induced by benzopyrene:** PI3K expression in rat cervical histology after benzopyrene injection and ZAM administration at different doses. The result in Fig. 2a showed that histology in the control group (K-) had complex cervical tissue with squamous epithelium containing cell nuclei and cytoplasm and stroma. Where this epithelium serves as a means of diagnostic information relating to the state of the cell. In the group of cancer model rats (K+) (Fig. 2b), cell abnormalities occurred with an enlarged nucleus and irregular cell shape. There was no significant difference ( $p < 0.01$ ) in PI3K expression between treatment groups. The lowest PI3K expression is at K+ (Fig. 2b), administration at dose P<sub>1</sub> (Fig. 2c) is not clear on the histological changes and the highest is at P<sub>2</sub> (Table 1 and Fig. 2c). The majority of PI3K expression at P<sub>2</sub> and P<sub>3</sub> (Fig. 2d and Fig. 2e) doses. In Fig. 3 also showed a Box plot of PI3K expression data in cervical tissue induced by benzopyrene. Based on Fig. 3, P<sub>2</sub> and P<sub>3</sub> were more expressed. After all, P<sub>2</sub> and P<sub>3</sub> doses were good doses for cervical tissue because these doses could reduce cervical cancer.

**Histology of cervical cells on Wnt expression induced by benzopyrene:** The result in Fig. 4 shows Wnt expression of rats cervical histology after benzopyrene injection and ZAM administration at different doses. K- has normal cervical tissue histology against a background of squamous epithelial cells with a central nucleus (Fig. 4a). The group of rats with cervical cancer (K+) had cell abnormalities with uncontrolled structural development, irregular cell shape, the inappropriate ratio of the cell nucleus to the cytoplasm, variations in the shape of the nucleus and enlargement of the nucleus (Fig. 4b). Administration at dose P<sub>1</sub> (Fig. 4c) is not clear on the histological changes. Wnt expression (marked with brown) was reduced in ZAM treatment at doses of 200 and 400 mg kg<sup>-1</sup> b.wt. (Fig. 4d and Fig. 4e) in cervical histology and increased in the cancer rats group (K+). Based on these data, the administration of ZAM showed a significant difference in cervical tissue after benzopyrene injection. The box plot showed a significant difference ( $p < 0.01$ ) with the Kruskal-Wallis test and the Mann-Whitney' follow-up test between each treatment (Table 2 and Fig. 5).



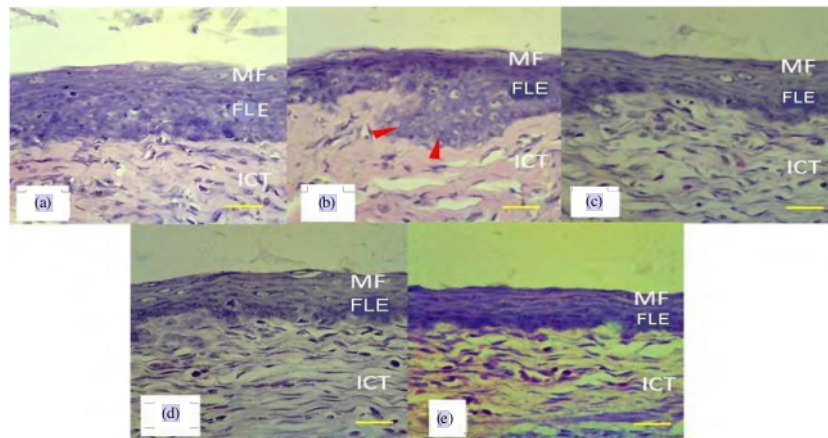


Fig. 1(a-e): Histology of cervical tissue induced by benzopyrene in several treatments with Haematoxylin Eosin (HE) staining (400x magnification), (a) K-: Control, (b) K+: Rats model of cancer, (c) P<sub>1</sub>: Rats model of cancer with a dose of 100 mg/b.wt. of ZAM, (d) P<sub>2</sub>: Rats model of cancer with a dose of 200 mg/b.wt. of ZAM and (e) P<sub>3</sub>: Rats model of cancer with a dose of 400 mg/b.wt. of ZAM

MF: Mucous folds, FLE: Flattened layered epithelium, ICT: Interstitial connective tissue, Arrow red: Insertion of cancer tissue and Yellow line: 200 μm

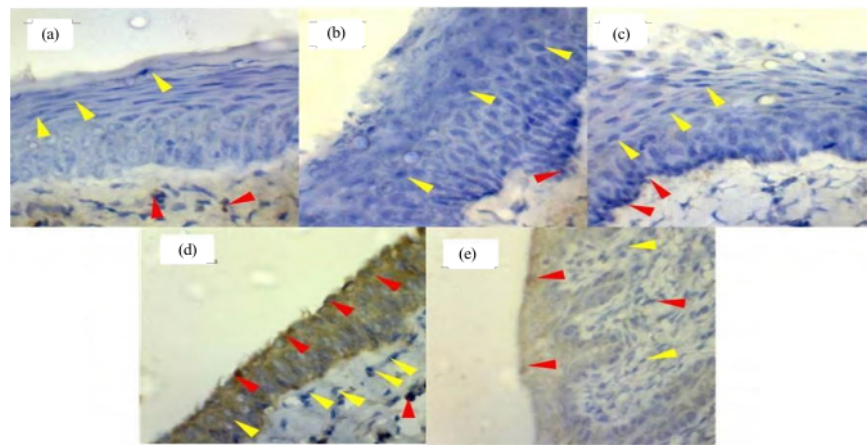


Fig. 2(a-e): Histology of cervical cells on PI3K expression induced by benzopyrene, (a) K-: Control, (b) K+: Rats model of cancer, (c) P<sub>1</sub>: Rats model of cancer with a dose of 100 mg/b.wt. of ZAM, (d) P<sub>2</sub>: Rats model of cancer with a dose of 200 mg/b.wt. of ZAM and (e) P<sub>3</sub>: Rats model of cancer with a dose of 400 mg/b.wt. of ZAM

MF: Mucous folds, FLE: Flattened layered epithelium, ICT: Interstitial connective tissue, Arrow red: Insertion of cancer tissue and Yellow line: 200 μm

Table 1: Kruskal-Wallis and Mann-Whitney analysis of PI3K expression in cervical tissue

| Groups         | Mean rank | Kruskal-Wallis | Mann-Whitney |       |                |                |                |
|----------------|-----------|----------------|--------------|-------|----------------|----------------|----------------|
|                |           |                | K-           | K+    | P <sub>1</sub> | P <sub>2</sub> | P <sub>3</sub> |
| K-             | 3.90      | 0.001          |              | 0.056 | 0.016*         | 0.008*         | 0.008*         |
| K+             | 10.00     |                |              |       | 0.690          | 0.008*         | 0.033*         |
| P <sub>1</sub> | 11.20     |                |              |       |                | 0.008*         | 0.039*         |
| P <sub>2</sub> | 22.20     |                |              |       |                |                | 0.066          |
| P <sub>3</sub> | 17.70     |                |              |       |                |                |                |

K-: Control, K+: Rats model of cancer, P<sub>1</sub>: Rats model of cancer with a dose of 100 mg/b.wt. of ZAM, P<sub>2</sub>: Rats model of cancer with a dose of 200 mg/b.wt. of ZAM and P<sub>3</sub>: Rats model of cancer with a dose of 400 mg/b.wt. of ZAM, (\*p<0.05, \*p<0.01)

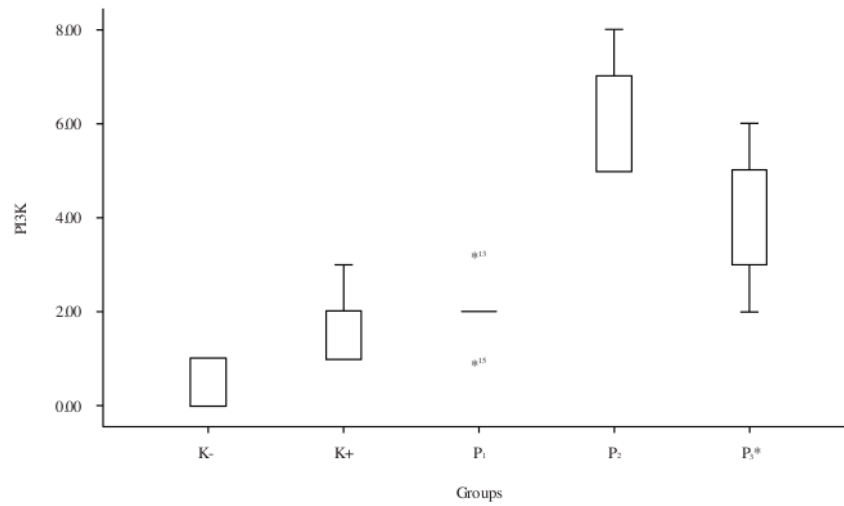


Fig. 3: Box plot of PI3K expression data in cervical tissue induced by benzopyrene, K- : Control, K+ : Rats model of cancer, P<sub>1</sub>: Rats model of cancer with a dose of 100 mg/b.wt. of ZAM, P<sub>2</sub>: Rats model of cancer with a dose of 200 mg/b.wt. of ZAM and P<sub>3</sub>: Rats model of cancer with a dose of 400 mg/b.wt. of ZAM  
\*p<0.01

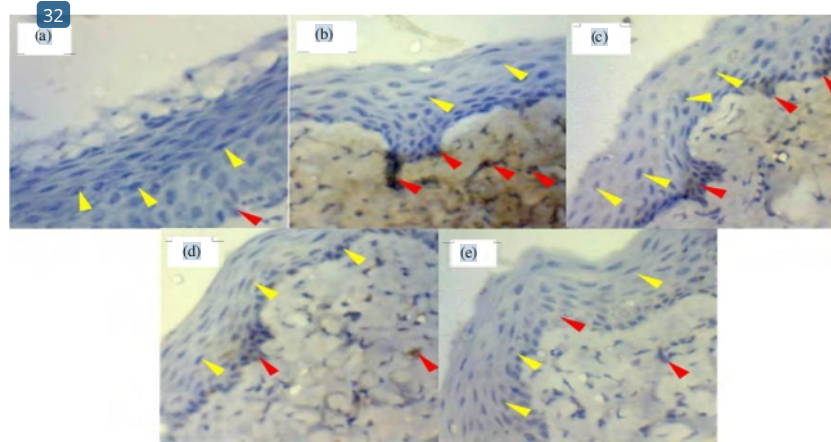


Fig. 4(a-e): Histology of cervical cells on Wnt expression induced by benzopyrene, (a) K-: Control, (b) K+ : Rats model of cancer (c) P<sub>1</sub>: Rats model of cancer with a dose of 100 mg/b.wt. of ZAM, (d) P<sub>2</sub>: Rats model of cancer with a dose of 200 mg/b.wt. of ZAM and (e) P<sub>3</sub>: Rats model of cancer with a dose of 400 mg/b.wt. of ZAM  
Yellow arrows: Negative expression and Red arrows: Positive expression

Table 2: Kruskal-Wallis and Mann-Whitney analysis of Wnt expression in cervical tissue

| Groups         | Mean rank | Kruskal-Wallis | Mann-Whitney |        |                |                |                |
|----------------|-----------|----------------|--------------|--------|----------------|----------------|----------------|
|                |           |                | K-           | K+     | P <sub>1</sub> | P <sub>2</sub> | P <sub>3</sub> |
| K-             | 5.40      | 0.001          |              | 0.008* | 0.008          | 0.095          | 0.421          |
| K+             | 22.50     |                |              |        | 0.032          | 0.008*         | 0.008*         |
| P <sub>1</sub> | 17.70     |                |              |        |                | 0.034*         | 0.014          |
| P <sub>2</sub> | 11.30     |                |              |        |                |                | 0.268          |
| P <sub>3</sub> | 8.10      |                |              |        |                |                |                |

K-: Control, K+: Rats model of cancer, P<sub>1</sub>: Rats model of cancer with a dose of 100 mg/b.wt. of ZAM, P<sub>2</sub>: Rats model of cancer with a dose of 200 mg/b.wt. of ZAM and P<sub>3</sub>: Rats model of cancer with a dose of 400 mg/b.wt. of ZAM, (\*p<0.05, \*p<0.01)

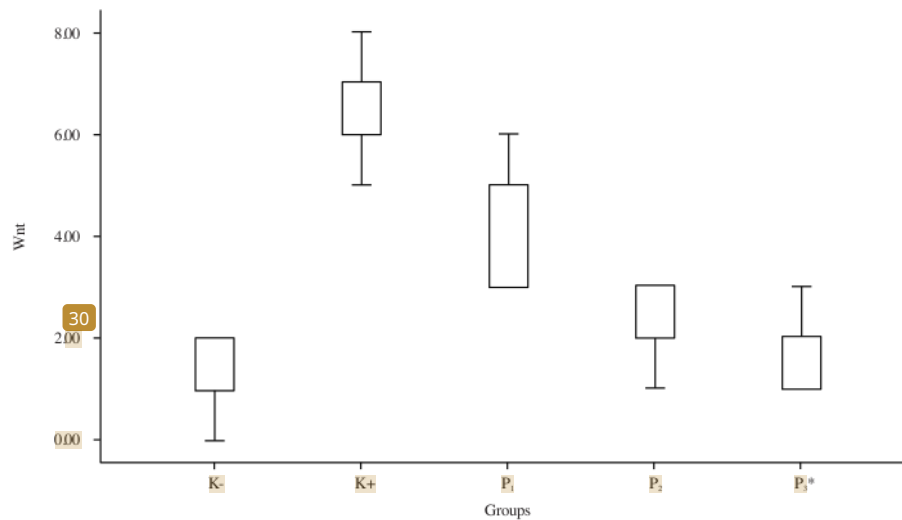


Fig. 5: Box plot of Wnt expression data in cervical tissue induced by benzopyrene, K-: Control, K+: Rats model of cancer, P<sub>1</sub>: Rats model of cancer with a dose of 100 mg/b.wt. of ZAM, P<sub>2</sub>: Rats model of cancer with a dose of 200 mg/b.wt. of ZAM and P<sub>3</sub>: Rats model of cancer with a dose of 400 mg/b.wt. of ZAM  
\*p<0.01

## DISCUSSION

Histopathologically, cervical cancer consists of various types. The two most common forms are squamous cell carcinoma and adenocarcinoma. About 85% are squamous (epidermoid) cervical carcinomas, 10% are adenocarcinomas and 5% are adenosquamous, clear cell, small cell, verrucous and others. In Fig. 1, the highest dose of ZAM P<sub>3</sub> (400 mg kg<sup>-1</sup> b.wt.) can improve the histopathology of cervical cancer because ZAM has high antioxidants, reduces MDA, is anti-inflammatory and increases HSP-70<sup>15</sup>. *Zanthoxylum acanthopodium* also contains bioactive compounds and is effective as an anticancer and inhibits apoptosis<sup>15,23</sup>.

Phosphatidylinositol-3-kinase (PI3K)/AKT/mammalian target rapamycin (mTOR) signalling is one of the most important intracellular pathways, which can be considered a master regulator for cancer<sup>24</sup>. A major effort for the development of drugs that target PI3K signalling is widely used in the evaluation of clinical trials and it is clear that PI3K inhibitors are effective in inhibiting tumour progression. PI3K inhibitors are divided into dual PI3K/mTOR inhibitors, pan-PI3K inhibitors and isoform-specific inhibitors<sup>24</sup>. The PI3K signalling pathway can regulate various physiological processes such as cancer<sup>28</sup> on the other hand, phosphorylated AKT activates glycogen synthase kinase 3 beta (GSK3β, serine/threonine-protein kinase), which promotes the transfer of erythroid

nuclear factor-2 (Nrf2) from the Keap1 binding site to the nucleus and then downstream target genes are transactivated via response relatively antioxidant elements (AREs) to inhibit oxidative stress<sup>25</sup>. Studies involving PI3K inhibitors may be limited by: Toxicity and it is, therefore, important to explore different dosing regimens, which can improve tolerability and optimize antitumour<sup>4</sup>. Based on the toxicity test, in addition to having high antioxidants, ZAM has low toxicity<sup>17</sup>, so that it can be developed molecularly to maintain or prevent cell growth into cancer.

Figures 4 and 5 show the histology and box plot of Wnt expression induced by benzopyrene. Cancer model rats have the highest Wnt expression and doses of P<sub>2</sub> and P<sub>3</sub> (200 and 400 mg kg<sup>-1</sup> b.wt.) can reduce Wnt expressions signalling is a promising therapeutic approach because of the potential of this strategy in eliminating cancer stem cells, which are sensitive to tumours resistant to conventional therapy<sup>26</sup>. Several genetic and biochemical studies have attempted to identify the components of the Wnt pathway and their functions<sup>27</sup>. With advances in sequencing technology and comprehensive structural characterization of the cancer genome, it is known that mutations in the Wnt pathway are common in human cancers. The Wnt pathway plays an important role during cell development<sup>26,27</sup>. This path falls into one of two categories: canonical or non-canonical<sup>28</sup>. The increase in Wnt expression is caused by the following factors:

Gene mutations, abnormalities in the mutation destroying complex in APC, overexpression of Wnt ligands, loss of inhibition as well as decreased activity of regulatory pathways<sup>8,16</sup>. Wnt/\$-catenin signal is activated in many types of cancer. Abnormal activation of the Wnt/\$-catenin pathway as a predisposing factor in many types of cancer such as cervical cancer<sup>10,27,28</sup>. Overexpression of these genes can alter developmental cell cycles and contribute to tumorigenesis. The suppression of Wnt expression by ZAM can be an alternative for developing cancer drugs through this pathway. Cause ZAM has high antiradical activity as anticancer<sup>15,23</sup>. This research implies that the presence of *Zanthoxylum acanthopodium* (Andaliman) fruit if further investigated can be used as a molecular cancer therapy and can be applied to cancer patients. It is recommended to continue to analyze the importance of this herb molecularly by other pathways. The limitations of this study are the need for genetic analysis, as well as the use of other antibodies that play a role in the Wnt and PI3K pathways so that the markers and pathways are more detailed.

## CONCLUSION

1 There was a significant difference between all groups ( $p < 0.001$ ) in Wnt and PI3K expression in cervical carcinoma. Dose 200 and 400 mg kg<sup>-1</sup> b.wt. of Andaliman (*Zanthoxylum acanthopodium*) extract increases PI3K expression through suppression of Wnt expression. It can be developed therapy molecularly to prevent cell growth into cancer.

## 6 SIGNIFICANCE STATEMENT

This study discovers that *Zanthoxylum acanthopodium* (Andaliman) fruits can as herbal for anticancer therapy molecularly. 6 This study will help the researcher to uncover the role of *Zanthoxylum acanthopodium* in molecular signalling of other target genes for drug development in cancer. Thus, a new theory on the role of Andaliman in the Wnt and PI3K pathways expression in cervical cancer may be arrived at.

## ACKNOWLEDGMENTS

This study received fund<sup>4</sup> support from the Research Proposal for Research from the Deputy for Strengthening Research and Development, Ministry of Research and Technology/National<sup>31</sup> research and Innovation Agency- DRPM (Number: 058/UN.5.2.3.1/PPM/KP-DRPM/2021).



# Suppression of Wnt Expression by Increasing PI3K in Rats Cervical Carcinoma by Andaliman (*Zanthoxylum acanthopodium*)

## ORIGINALITY REPORT

12%

SIMILARITY INDEX

9%

INTERNET SOURCES

7%

PUBLICATIONS

6%

STUDENT PAPERS

## PRIMARY SOURCES

|   |   |     |
|---|---|-----|
| 1 | Submitted to University of Southern Queensland<br>Student Paper   | 1%  |
| 2 | coek.info<br>Internet Source  | 1%  |
| 3 | Submitted to Alexandru Ioan Cuza University of Iasi<br>Student Paper  | 1%  |
| 4 | journal.ipb.ac.id<br>Internet Source  | 1%  |
| 5 | perpustakaan.poltekkes-malang.ac.id<br>Internet Source  | 1%  |
| 6 | Sanjay Kumar Jaiswal, Akhil Anand, Akhouri Vaishampay. "Response of Soybean ( <i>Glycine max</i> L. Merr) Cultivars to Soil Microsymbionts Inoculation in Agriculture Field in India", <i>Journal of Plant Sciences</i> , 2016<br>Publication | <1% |

|    |   |      |
|----|---|------|
| 7  | <a href="http://journal.universitaspahlawan.ac.id">journal.universitaspahlawan.ac.id</a><br>Internet Source   | <1 % |
| 8  | Animesh Mandal, Deepak Bhatia, Anupam Bishayee. "Simultaneous disruption of estrogen receptor and Wnt/ $\beta$ -catenin signaling is involved in methyl amooranin-mediated chemoprevention of mammary gland carcinogenesis in rats", <i>Molecular and Cellular Biochemistry</i> , 2013<br>Publication | <1 % |
| 9  | Submitted to Universitas Negeri Jakarta<br>Student Paper  | <1 % |
| 10 | Submitted to University of Newcastle upon Tyne<br>Student Paper   | <1 % |
| 11 | <a href="http://www.omicsdi.org">www.omicsdi.org</a><br>Internet Source   | <1 % |
| 12 | <a href="http://www.researchsquare.com">www.researchsquare.com</a><br>Internet Source   | <1 % |
| 13 | Submitted to Bilkent University<br>Student Paper  | <1 % |
| 14 | <a href="http://ictromi.usu.ac.id">ictromi.usu.ac.id</a><br>Internet Source   | <1 % |
| 15 | <a href="http://journals.plos.org">journals.plos.org</a><br>Internet Source   | <1 % |

|    |   |      |
|----|---|------|
| 16 | Submitted to Hong Kong Baptist University<br>Student Paper  | <1 % |
| 17 | clinmedjournals.org<br>Internet Source  | <1 % |
| 18 | topsecretapiaccess.dovepress.com<br>Internet Source   | <1 % |
| 19 | www.frontiersin.org<br>Internet Source  | <1 % |
| 20 | 123dok.com<br>Internet Source   | <1 % |
| 21 | Submitted to University of Lancaster<br>Student Paper   | <1 % |
| 22 | Tingting Wu, Wenning Wu, Shiyu Jin, Qunyan Zhang, Siqi Ding, Chuan Wu, Xiuyun Zheng, Chunfeng Fu, Quancheng Han, Xiaoyu Liu. "Effect of Vanillin on Emotional Stress and Pain-Related Behaviours Induced by Experimental Tooth Movement in Rats", Research Square Platform LLC, 2023<br>Publication | <1 % |
| 23 | gamma-web.iacs.umd.edu<br>Internet Source   | <1 % |
| 24 | scholar.sun.ac.za<br>Internet Source  | <1 % |

25 Emmanuel Arthur, George Obeng-Akrofi, Edward A. Awafo, Joseph O. Akowuah. "Comparative assessment of three storage methods for preserving maize grain to enhance food security post COVID-19", *Scientific African*, 2023  
Publication

---

26 Suresh Varma Penumathsa. "Resveratrol enhances GLUT-4 translocation to the caveolar lipid raft fractions through AMPK/AKT/eNOS signaling pathway in diabetic myocardium", *Journal of Cellular and Molecular Medicine*, 2/6/2008  
Publication

---

27 [papersearch.net](http://papersearch.net)  
Internet Source

---

28 [www.molecularcircuit.com](http://www.molecularcircuit.com)  
Internet Source

---

29 [purehost.bath.ac.uk](http://purehost.bath.ac.uk)  
Internet Source

---

30 [repository.ub.ac.id](http://repository.ub.ac.id)  
Internet Source

---

31 Evi Triwulandari, Widya Fatriasari, Apri Heri Iswanto, Melati Septiyanti, Eko Fahrul Umam, Muhammad Ghozali. "Effect of Reaction Time on the Molecular Weight Distribution of

# Polyurethane Modified Epoxy and its Properties", Journal of Materials Research and Technology, 2022

Publication

---

32

jpels.org  
Internet Source

<1 %

---

---

Exclude quotes      On

Exclude matches      Off

Exclude bibliography      On