

MMP-9 and GLUT-1 Expression in histology Changes of Cervical Carcinoma as a result of Zanthoxylum acanthopodium

by Herma Yerni

Submission date: 09-Nov-2021 04:10AM (UTC-0800)

Submission ID: 1697690511

File name: MMP-9_n_Glut-1-Main_article_Q2_Rostime_no_title.docx (8.08M)

Word count: 4122

Character count: 21964

Abstract

Cervical cancer is one of the most common cancers in Indonesia, with an increase that continues year after year. Cervical cancer can be treated with molecular therapies such as MMP-9 and GLUT-1, which are enzymes involved in tumour cell invasion, metastasis, and angiogenesis. *Zanthoxylum acanthopodium* (Andaliman) is an Indonesian herbal with anti-cancer properties. The aim of this study was to look at the histological changes caused by andaliman treatment on MMP-9 and GLUT-1 expression. This study used rats divided into five groups: control (C-), cancer model (C+), cancer rats with a dose of ZAM 100mg/BB (ZAM100), cancer rats with a dose of ZAM 200 mg/BW ZAM (ZAM200), and cancer rats with a dose of ZAM 400 mg/BB ZAM (ZAM400). Immunohistochemistry was used to stain cervical tissue with MMP-9 antibody and GLUT-1, as well as the Tunnel assay for cell apoptosis. As a result, ZAM administration had no effect on mouse body weight but had a significant effect on cervical cancer weight ($p < 0.05$), and there was an increase in MDA levels associated with SOD deficiency in tumor tissue. SOD activity increased as a result of ZAM administration, allowing cells to be protected from oxidant disruption and oxidative stress. ZAM significantly reduced MMP-9, GLUT-1 expression, and apoptosis in cancer tissue ($p < 0.01$). Carcinoma has spread to the pelvic wall, there is no clear space between the tumor and the pelvic wall, and the core is irregular. Because ZAM contains powerful antioxidants, it can reduce the expression of MMP-9 and GLUT-1. An effective cancer treatment strategy may include the use of appropriate antioxidant inhibitors and/or free radical-producing compounds. Finally, ZAM can be targeted in cervical cancer molecular therapy.

Key Words: Apoptosis; Cervical Cancer; GLUT-1; MMP-9; Zanthoxylum

INTRODUCTION

Cervical cancer is the second most frequent cancer among Indonesian women, after breast cancer, with a 23.4/100,000 population incidence rate and a 13.9/100,000 population mortality rate. According to current estimates from the Indonesian Ministry of Health, the number of new women diagnosed with cervical cancer ranges from 90-100 cases per 100,000 population, with 40 thousand cases diagnosed each year. Some of the factors that cause cervical cancer include women's delayed detection due to a lack of knowledge about cervical cancer, for example, keeping the female area (vagina) clean is very important, especially for women.

Matrix Metalloproteinase 9 (MMP-9) is a proteolytic enzyme that is thought to play an important role in the progression of precancerous lesions to cervical cancer. MMP-9 levels above a certain threshold accelerate the degradation of cervical tissue and facilitate cancer cell invasion. MMPs are normally formed only at the time and location of tissue remodelling. MMPs, on the other hand, are formed and play a role in pathological conditions such as tumour cell invasion, metastasis, and angiogenesis. In pathological processes such as cancer, the activating process of MMP largely bypasses the normal activating process. MMP9 gelatinase or collagenase has a high ability in the gelatinolytic process that degrades collagen, fibronectin, and elastin, causing MMP9 expression to increase in the inflammatory and tumour malignancy processes.

Glucose transporter-1 (GLUT-1) is a protein found in most normal tissues. GLUT-1 is normally not detectable in normal epithelial tissue or benign epithelial tumours. Glucose is the most important source of energy for cells. Cancer cells frequently have high glucose metabolism values when compared to normal cells to support their proliferative ability. In various types of cancer, GLUT-1 overexpression is a significant limiting factor in the rate of glucose transport in tumour cells. Overexpression of glucose transporters (GLUTs), a protein family responsible for glucose uptake, increases cancer aerobic glycolysis.

The Indonesian spice andaliman (*Zanthoxylum acanthopodium*) grows wild in the North Sumatra region (Djati, and Christina, 2019). Antioxidants contained in *Zanthoxylum acanthopodium* include alkaloids, glycosides, tannins, phenols, and flavonoids, which act as natural preservatives, anti-inflammatory, and antibacterial agents (Wijaya et al., 2019). In cervical cancer tissue, *Zanthoxylum acanthopodium* can also change the Mef-7 Cell Line and mend the tissue (Arsita et al., 2019; Simanullang et al., 2021a). This plant can improve placental tissue histology, rat kidney and liver hypertension, human trophoblast Hes1 and Notch1 genes, and burn diabetes, among other things (Situmorang et al., 2019a; Situmorang et al., 2019b; Situmorang et al., 2019c; Situmorang dkk., 2021a; Situmorang dkk., 2021b; Manurung dkk., 2021). The goal of this study was to look at the histological changes in cervical cancer tissue in terms of MMP-9 and GLUT-1 expression, as well as apoptosis in cervical tissue after andaliman treatment. As a result, it is hoped that research on cancer cells will continue and that this plant will be developed into cervical cancer drugs using molecular therapy in the future.

MATERIAL AND METHODS

Materials

Andaliman was originally in Berastagi, North Sumatera Province, Indonesia. Rabbit Polyclonal GLUT1 IHC Antibody (Catalog Number: IW-PA1120) Storage: Keep at 2-8 °C. Do not allow to freeze (Company: IHC WORLD, LLC Ellicott City, MD 21042, USA). Rabbit polyclonal MMP9 antibody (ab237782), Catalog number: EPR22140-154 - BSA and Azide free (Office: Abcam, Cambridge Biomedical Campus Cambridge CB2 0AX, UK). ab96755 is a rabbit polyclonal

antibody to Cellular Apoptosis Susceptibility/CSE1L. (Office: Abcam, Cambridge Biomedical Campus Cambridge CB2 0AX, UK).

Preparation of Zanthoxylum acanthopodium methanol extract (ZAM)

Fruits of *Zanthoxylum acanthopodium* (andaliman) are cleaned of any soil or dust that has adhered to them. To make the fruit methanol extract, the following three steps are taken: (1), Drying the crude: the andaliman fruit is cleaned and drained before being mashed in a blender. (2), Andaliman extract is created by macerating Andaliman fruit in 96 percent methanol for one night. It is then allowed to percolate until it becomes clear. The powder extracts are obtained by evaporating the concentrated liquid (3), because the Andaliman extract does not completely dissolve in water, a homogeneous mixture is obtained by combining it with a suspending agent CMC 1.5 percent to 1.0 percent or 1 ml in 150 ml of distilled water. The dregs are washed with a 96 percent methanol solvent before being transferred to a closed container and kept in a cool, dark place for two days.

Experimental Animals

The research was conducted at the University of Sumatera Utara's Biology Laboratory and the Pathology and Anatomy Laboratory of the Faculty of Medicine from March to September 2021. During 30 days of the administration, there are five groups of rats: the control group is Group C-, the cancer model group is Group C+, the ZAM100 group is cancer rats with a dose of 100mg/BW of ZAM, the ZAM200 group is cancer rats with a dose of 200 mg/BW of ZAM, and the ZAM400 group is cancer rats with a dose of 400 mg/BW of ZAM. On the 30th day after ZAM administration, the rats are dissected. Immunohistochemistry and the Tunnel assay are used to stain the cervical tissues. The Ethics Committee for Handling Experimental Animals, Faculty of Mathematics and Natural Sciences, USU, approved this research (Ethical Clearance: No. 0262/KEPH-FMIPA/2021).

Rats model of cervical cancer

The University of Sumatera Utara's Animal House Laboratory furnished 36 rats (*Rattus norvegicus*) measuring 180-200g for this study. Prior to the study, the rats are fed standardized rat pellets and given enough water every day, being acclimated to laboratory settings for four weeks. The rats are created in a cancer animal model by injecting benzopyrene 50 mg/BW into the cervix and allowing the tumour to grow for three months.

Measurement of SOD and MDA

The sample was homogenized for 5 minutes in a homogenizer tissue with 10 ml of PBS pH 7.4, the supernatant was collected and SOD, and MDA levels were measured using an ELISA reader at 450 nm.

Immunohistochemistry

A microtome was used to cut 4 micron-thick paraffin cervical tissue. For pre-treatment, the tissue was heated in citrate buffer at pH 6.0 and 350W. Following a PBS wash, the tissue was incubated with MMP-9 and Glut-1 antibodies at 37 °C before being treated with avidin-biotin-peroxidase. 3,3-Diaminobenzidine (DAB) hydrochloride was used for the chromogenic visualisation reaction, which was then stained with haematoxylin Mayer (Situmorang et al., 2021a). The cervical tissue on the slide was stained with hematoxylin, and the score was calculated by multiplying the positive result by the staining intensity, 0 indicates that less than 10% of the cells were stained, 1 indicates

that 10% to 25% of the cells were stained, 2 indicates that 25% to 50% of the cells were stained, 3 indicates that 50% to 75% of the cells were stained, and 4 indicates that more than 75% of the cells were stained. The staining intensity was graded as 1 (weak), 2 (moderate), and 3 (strong).

TUNEL assay

For the study of apoptotic cells, the cervical tissue was stained with the TUNEL assay technique. Cervix-containing slides were immersed in xylene for 5 minutes, then rehydrated with graded ethanol and rinsed with 0.85 percent PBS. Slides were incubated for 15 minutes with Proteinase K. For one hour, the diluted rTdT reaction mixture was applied to the final label. Before endogenous peroxidase synthesis, the slide was submerged in buffer for 15 minutes at room temperature and then rinsed with PBS. The tissue is incubated at room temperature for 30 minutes in this procedure. 3,3-diaminobenzidine hydrochloride (DAB) is utilized in the chromogenic imaging reaction. The slides were immersed in ethanol and xylene before being coated with glass. Using a light microscope, the researcher saw five fields of view.

Statistical analysis of data

The Anova test and the *Kruskal Wallis* test (for non-parametric data) were used to analyze the data in the SPSS 22 program.

RESULTS

The Body and cervical weight in cancer model rats

Table 1. Body and Cervical Weight after given ZAM

Treatment	Body Weight (BW)		Cervical Weight (g)
	Before (g)	After (g)	
C-	189.20 ± 7=8.22	200.98 ± 12.70	0.30 ± 0.03
C+	200.23 ± 9.21 ^{ns}	210.21 ± 9.59 [#]	1.66 ± 0.14 ^{**}
ZAM100	201.73 ± 11.89 ^{ns}	212.22 ± 11.25 ^{ns}	1.07 ± 0.06 [*]
ZAM200	201.77 ± 21.88 ^{ns}	221.44 ± 11.33 ^{ns}	0.69 ± 0.12 [*]
ZAM400	199.42 ± 23.22 ^{ns}	212.93 ± 12.10 ^{ns}	0.32 ± 0.10 ^{**}

C-: Control, C+: rats model of cancer ZAM100: rats model of cancer with a dose of 100mg/BW of ZAM, ZAM200: rats model of cancer with a dose of 200 mg/BW of ZAM, ZAM400: rats model of cancer with a dose of 400 mg/BW of ZAM (#P<0.05 versus C-, ##P<0.01 versus C-, *P<0.05 versus C+, **P<0.01 Versus C+, ^{ns}P>0.05).

Table 1 showed that body and cervical weight in cancer model rats rats. Insignificant difference (P> 0.05) on before injection of benzopyrene 50 mg/BW in cervical, but after injection of benzopyrene, there was a significant difference between group C- versus C+ (P<0.05, F=0.04). Table 1 also showed that cervical weight in C- versus C+ (P <0.01, F=0.004), ZAM100 (P<0.05, F=0.03), ZAM200 (P<0.01, F=0.03) and ZAM400 (P<0.01, F=0.004) versus C+. The injection of benzopyrene 50 mg/BW and given ZAM in cervical tissue affects body weight and cervical weight significantly in rats.

Measurement of Superoxide Dismutase (SOD) and Malondialdehyde (MDA) in cancer model rats.

There was a significant difference in SOD and MDA levels in cancer rats compared to the C- group ($P < 0.05$, $p = 0.035$), with cancer rats having lower SOD levels. SOD levels increased in cancer rats given ZAM at a dose of 100 mg/kg BW, but decreased as the dose increased to 400 mg/kg BW (Figure 1a). This contrasts with the increased MDA levels in cancer Rats, which showed a significant difference between C- versus C+ ($p > 0.01$, $p = 0.006$) (Figure 1b), and ZAM administration at doses ranging from 100 to 400 reduced MDA levels in cancer Rats. Based on these findings, it is known that ZAM at a dose of 100 to 400 mg/Kg BW can be used to increase SOD and MDA levels in cancer rats.

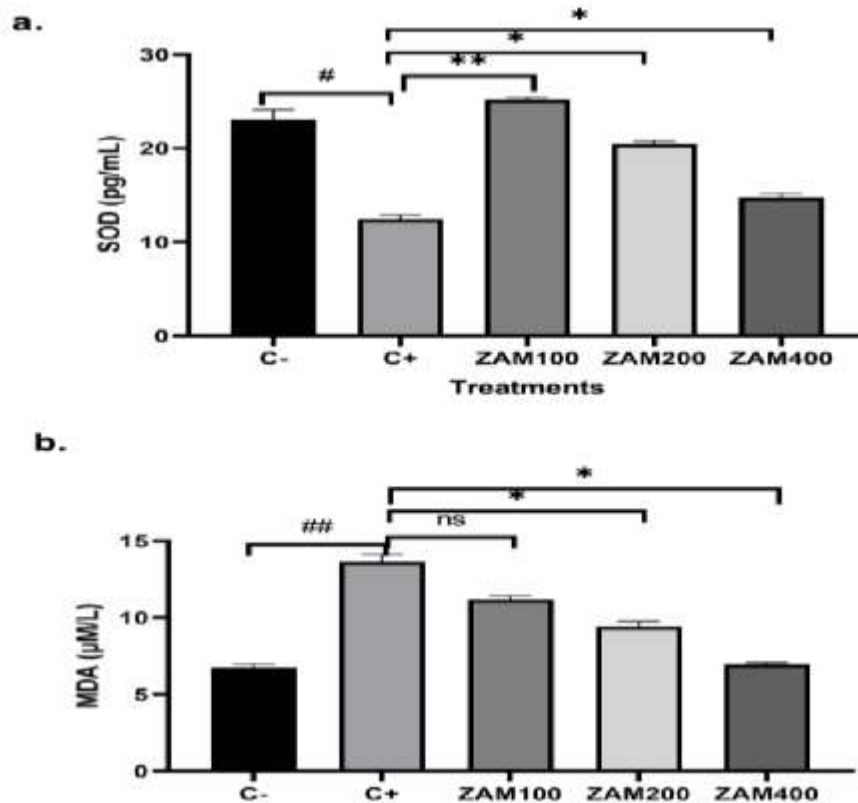


Figure 1. Levels of Superoxide Dismutase (SOD) and Malondialdehyde (MDA) in cancer model rats. a. SOD, b. MDA. C-: Control, C+: rats model of cancer ZAM100: rats model of cancer with a dose of 100mg/BW of ZAM, ZAM200: rats model of cancer with a dose of 200 mg/BW of ZAM, ZAM400: rats model of cancer with a dose of 400 mg/BW of ZAM (# $P < 0.05$ versus C-, ## $P < 0.01$ versus C-, * $P < 0.05$ versus C+, ** $P < 0.01$ versus C+, ^{ns} $P > 0.05$).

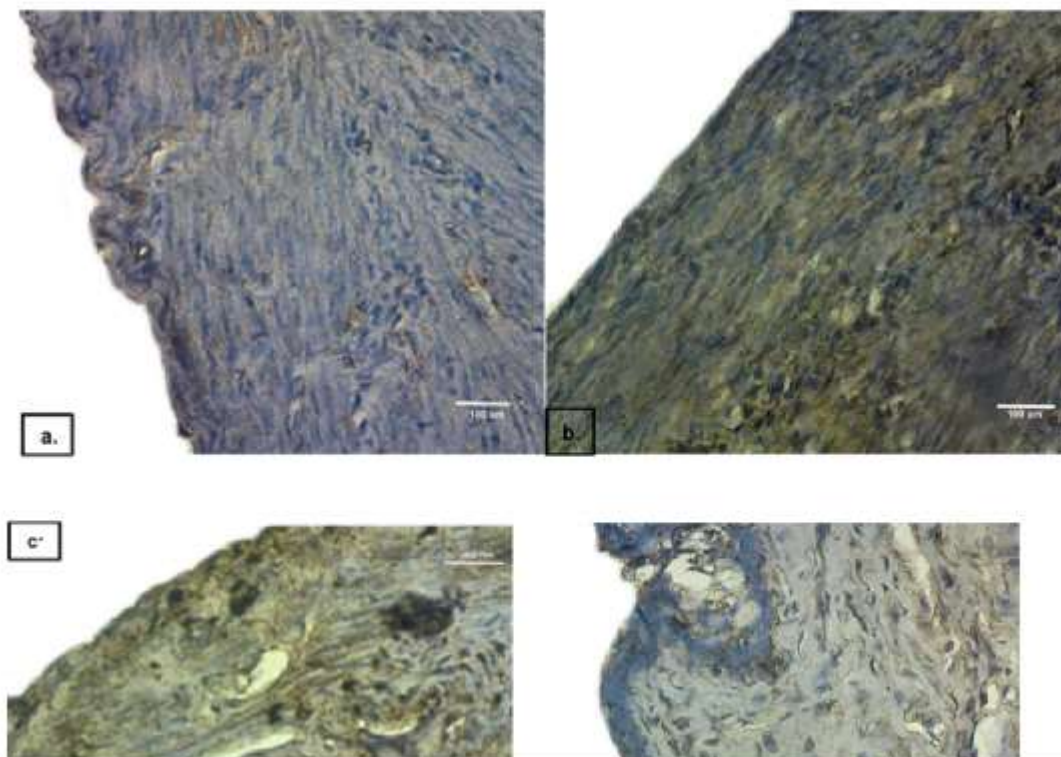
MMP- 9 expression in histological changes of cervical cancer after ZAM administration.

Based on *Kruskal Wallis* test, as shown in Table 2, revealed a statistically significant difference with $p < 0.00$. According to the average value, there is a significant difference in MMP-9 expression ($p < 0.01$) versus C-. The lowest dose of ZAM (100mg/kgBW) was not significant (P0.05), but doses of 200 and 400 mg/kgBW were ($P < 0.05$). Cervical cells in group C- had normal epithelial and nuclear layers on histology (Figure 2a). In contrast, in Figure 2b, undifferentiated cells are confined to the lower layers of the epithelium and develop mitotic features. Lower epithelial cell changes were characterized by epithelial thickening and increased MMP-9 expression. MMP-9 expression in cancer tissue decreased as ZAM dose increased. ZAM (Figure 2c-2e) administration at different doses reduced the number of nuclei stained brown by immunohistochemistry, indicating a positive index of MMP-9 expression in cancer tissue. Carcinomas that were previously uncontrollably spreading in the untreated group of cancers have now slowed and no longer developed into epithelium. According to Table 2 and Figure 2, the administration of ZAM, particularly at a dose of 400mg/kg BW, can suppress the expression of MMP-9 in cervical cancer histological changes.

Table 2. Kruskal Wallis and Mann-whitney analysis of MMP-9 expression in carcinoma cervical

Groups	Mean \pm SD	Kruskal-Wallis	Mann-Whitney (p-value)				
			C-	C+	ZAM100	ZAM200	ZAM400
C-	14.80 \pm 4.11			0.001	0.001	0.020	0.056
C+	42.30 \pm 7.21 ^{##}				0.070	0.030	0.001
ZAM100	40.80 \pm 7.19 ^{##}	0.000				0.030	0.020
ZAM200	22.67 \pm 4.71 [*]						0.040
ZAM400	19.41 \pm 3.22 ^{**}						

C-: Control, C+: rats model of cancer ZAM100: rats model of cancer with a dose of 100mg/BW of ZAM, ZAM200: rats model of cancer with a dose of 200 mg/BW of ZAM, ZAM400: rats model of cancer with a dose of 400 mg/BW of ZAM (#P<0.05 versus C-, ##P<0.01 versus C-, *P<0.05 versus C+, **P<0.01 Versus C+, ^{##}P>0.05).



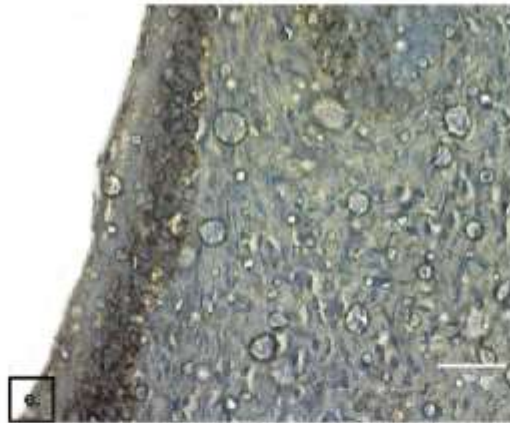


Figure 2. MMP-9 Expression in Histology changes of cervical cancer model rats. a. Control (C-), b. rats model of cancer (C+), c. rats model of cancer with a dose of 100mg/BW of ZAM (ZAM100), d. rats model of cancer with a dose of 200 mg/BW of ZAM (ZAM200), e.rats model of cancer with a dose of 400 mg/BW of ZAM (ZAM400). MMP-9 expression is indicated by a brown-black color in histology (400x).

GLUT-1 expression in histological changes of cervical cancer after ZAM administration

Table 3 shows that both the Kruskal Wallis test and the Mann-Whitney follow-up test revealed significant differences. According to the mean values, there was a significant difference ($p < 0.001$) in GLUT-1 expression between the C+ and C- groups. It was, however, not significant at the lowest ZAM dose (100mg/kg BW) but significant at 200 and 400 mg/kgBW ($P < 0.01$). The C+ group had the highest level of GLUT-1 expression, while the C- group had the lowest level of expression, even when it was not expressed. Figure 3a showed normal histological changes, but the carcinoma had spread to the pelvic wall, there was no clear space between the tumor and the pelvic wall, and the core was irregular (Figure 3b). This was in stark contrast to the C-group histology, which showed that cervical tissue still contained normal cells (Figure 3a). The lesions were larger than in the control group at the lowest ZAM dose (Figure 3c), but GLUT-1 expression began to decrease. The reduction in GLUT-1 expression at doses of 200 and 400 mg/kg BW (Figure 3d-3e) showed that this herb could significantly reduce GLUT-1 expression because the empty space between tumors was reduced, the carcinoma stopped developing, and the nucleus began to form normally. Thus, administration of ZAM doses of 200 and 400 mg/kg BW can reduce GLUT-1 expression and improve histology in cervical cancer rats, according to Table 3 and Figure 3.

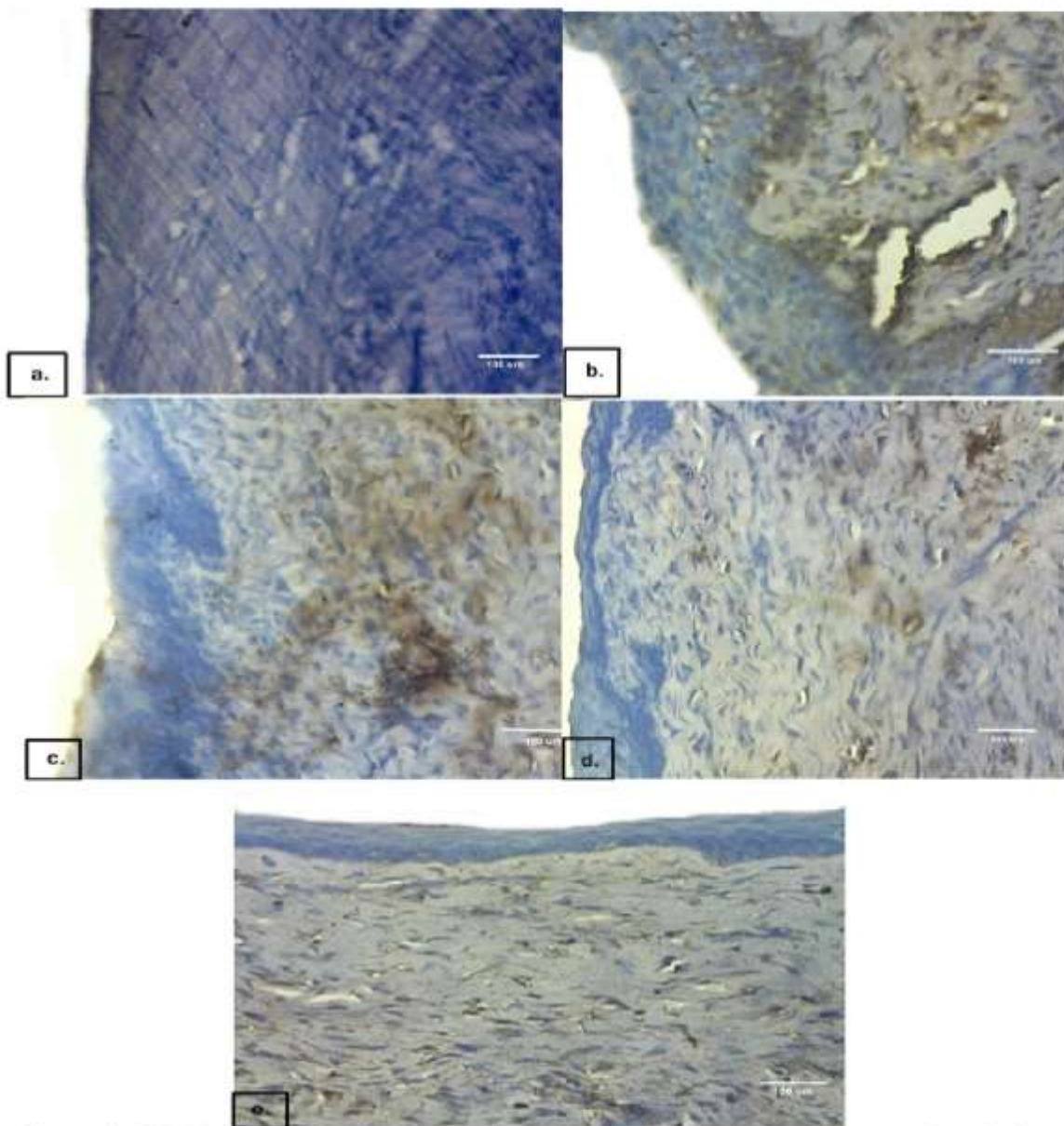


Figure 3. GLUT-1 Expression in Histology changes of cervical cancer model rats. a. Control (C-), b. rats model of cancer (C+), c. rats model of cancer with a dose of 100mg/BW of ZAM (ZAM100), d. rats model of cancer with a dose of 200 mg/BW of ZAM (ZAM200), e. rats model of cancer with a dose of 400 mg/BW of ZAM (ZAM400). GLUT-1 expression is indicated by a brown-black color in histology (400x).

Table 3. Kruskal Wallis and Mann-whitney analysis of GLUT-1 expression in carcinoma cervical

Groups	Mean \pm SD	Mann-Whitney (p-value)
--------	---------------	------------------------

		Kruskal-Wallis	C-	C+	ZAM100	ZAM200	ZAM400
C-	1.45 ± 0.12			0.000	0.001	0.001	0.001
C+	30.92 ± 2.25 ^{###}				0.056	0.002	0.002
ZAM100	22.80 ± 3.11 ^{ns}	0.000				0.040	0.040
ZAM200	12.67 ± 2.21 ^{**}						0.056
ZAM400	10.42 ± 1.34 ^{**}						

C-: Control, C+: rats model of cancer ZAM100: rats model of cancer with a dose of 100mg/BW of ZAM, ZAM200: rats model of cancer with a dose of 200 mg/BW of ZAM, ZAM400: rats model of cancer with a dose of 400 mg/BW of ZAM (#P<0.05 versus C-, ###P<0.001 versus C-, **P<0.01 Versus C+, ^{ns}P>0.05).

Apoptotic cells in histological changes of cervical cancer after ZAM administration.

Figure 4 depicts the apoptotic histology of the rat cervix following benzopyrene injection and ZAM administration at various doses. The histology of cervical tissue in Group C- (Figure 4a) was healthy and normal, but it changed dramatically after benzopyrene (C+) injection. Figure 4b depicts the histology of the cervix, with an irregular shape of the cell nucleus forming bubbles known as apoptotic bodies. The environment within the cell nucleus appears to be disjointed and karyorrhexis. Because the protein structures that make up the cytoskeleton are digested by a specific peptidase enzyme (caspase) that has been activated in the cell, the cell becomes circular (red arrow). Histological features differed significantly between treatments (P<0.05). According to the statistical data (Table 4), ZAM100 and ZAM200 had the highest apoptosis when compared to ZAM400 (Figure 4c-4e). This was due to the fact that the 400 dose was the highest, so there was little cell apoptosis in the tissue's histology.

Table 4. Kruskal Wallis and Mann-whitney analysis of TUNEL expression on cervical tissue

Groups	Mean ± SD	Kruskal-Wallis	Mann-Whitney (p-value)				
			C-	C+	ZAM100	ZAM200	ZAM400
C-	7.30 ± 0.12			0.040	0.045	0.03	0.06
C+	18.30 ± 2.25 [†]				0.06	0.04	0.002
ZAM100	12.80 ± 3.11 ^{ns}	0.000				0.04	0.04
ZAM200	10.67 ± 2.21 [*]						0.05
ZAM400	9.42 ± 1.34 ^{**}						

C-: Control, C+: rats model of cancer ZAM100: rats model of cancer with a dose of 100mg/BW of ZAM, ZAM200: rats model of cancer with a dose of 200 mg/BW of ZAM, ZAM400: rats model of cancer with a dose of 400 mg/BW of ZAM (#P<0.05 versus C-, *P<0.05 versus C+, **P<0.01 Versus C+, ^{ns}P>0.05).

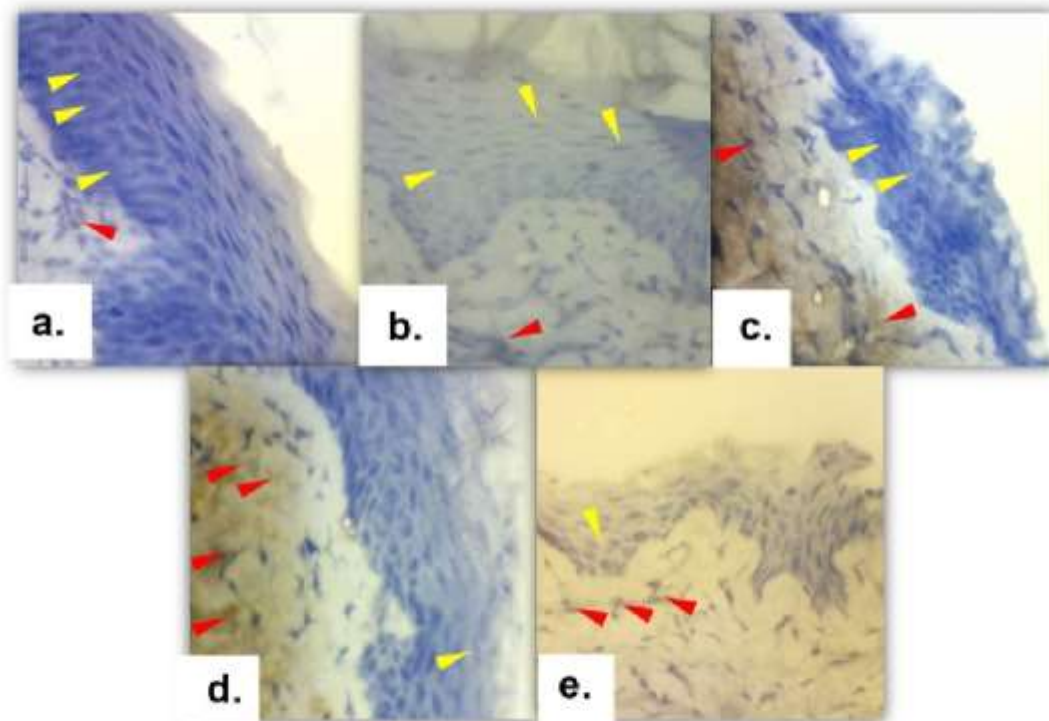


Figure 4. Apoptotic cells in Histology changes of cervical cancer model rats. a. Control (C-), b. rats model of cancer (C+), c. rats model of cancer with a dose of 100mg/BW of ZAM (ZAM100), d. rats model of cancer with a dose of 200 mg/BW of ZAM (ZAM200), e. rats model of cancer with a dose of 400 mg/BW of ZAM (ZAM400). Yellow arrows indicate low expression of apoptosis in tissues, while red arrows indicate high expression (400x).

DISCUSSION

The bodyweight of cervical cancer rats had no effect on the administration of ZAM at doses ranging from 100 to 400mg/Kg BW. Weight may be an important factor for cancer patients. However, in cervical cancer rats, it was not significant (Clarke et al., 2018). This could be due to the small size of cervical cancer, rats fat, or excessive rats activity. Cervical tumours can influence cervical weight in both the control and ZAM groups. Tumour cells can proliferate indefinitely and exhibit excessive angiogenesis. When this happens in specific areas of the tumour, there is a deficiency of nutrients, including oxygen. Tumour cells enter a resting phase during which oxygen is depleted, causing them to become hypoxic or even anoxic, and necrosis occurs (Clarke et al., 2018).

ZAM was more effective in cervical cancer rats at doses of 100 and 200 mg/kg BW for SOD levels and 200 and 400 mg/kg BW for MDA levels. Increased lipid peroxide due to antioxidant deficiency is linked to increased circulating levels of Malondialdehyde (MDA) and decreased Superoxide dismutase (SOD) activity in cervical cancer (Sherif, et al., 2018; Thakur et al., 2015). Furthermore, elevated MDA levels in tumor tissue may be linked to SOD deficiency. If this continues, superoxide anions, which are highly radical and capable of penetrating membranes, accumulate, causing negative effects away from the tumor (Sherif, et al., 2018). Antioxidants

found in andaliman can lower MDA levels, increasing SOD activity. It is possible to protect cells from oxidant interference and oxidative stress as a result of ZAM administration by increasing SOD activity, which can lead to a variety of diseases, including cancer. ZAM can be used to control the state of these cells because it contains powerful antioxidants that can counteract free radicals (Situmorang et al., 2020).

The administration of ZAM, particularly at a dose of 400mg/kg BW, can suppress the expression of MMP-9 in cervical cancer histological changes. The greater the immunohistochemical positivity of MMP-9, as measured by intensity and quantity, the more severe the cervical neoplastic lesions. MMP-9 immunohistochemical expression is elevated in cervical tumors, which plays an important role in carcinogenesis. Cervical carcinoma can be polypoid or infiltrative on the macroscopic level. When compared to polypoid tumors, infiltrative tumors will invade and damage the surrounding tissue structure. Microscopically, this enlargement, rough chromatin, and prominent nucleoli can be seen throughout the thickness of the squamous epithelial layer. The ability of the body to degrade MMP is highly dependent on the balance of active enzymes and natural inhibitors. MMP causes damage to the basement membrane of blood vessel walls, allowing tumor cells to enter and exit the bloodstream (intravasation and extravasation), MMPs are also involved in the modification of new microenvironments at metastasis sites. This will aid in the growth of metastatic tumor cells in their new environment. Because ZAM contains powerful antioxidants, it can reduce MMP-9 expression. An effective cancer treatment strategy may include the use of appropriate antioxidant inhibitors and/or free radical-producing compounds. Herbs from the genus *Zanthoxylum* have anti-inflammatory, analgesic, antinociceptive, antioxidant, antibiotic, hepatoprotective, antiplasmodial, cytotoxic, antiproliferative, anthelmintic, larvicidal, antiviral, and anticancer properties in addition to antioxidants (Wijaya et al., 2019; Situmorang et al., 2020).

In cervical cancer mice, ZAM administration can reduce GLUT-1 expression and improve histology. The expression of GLUT1 in cancer can be an indication of a tumor's metabolic and vascular requirements, which has clinical implications for survival and treatment plans. Given the importance of GLUT1 in oncogenesis, several studies have been conducted to investigate GLUT1's prognostic value in tumors. GLUT1 overexpression may be linked to increased glucose metabolism in cancer cells. Cancer cell metabolism has been reprogrammed to promote cancer cell proliferation. Several studies have found that many metabolic genes play important roles in cancer development and could be used as prognostic markers as well as therapeutic targets. Glucose is the most important source of energy for cells. Cancer cells frequently have high glucose metabolism values when compared to normal cells to support their proliferative ability. Antioxidants have been shown to reduce toxic side effects during cancer treatment. The antioxidant intervention stems from the fact that plants containing antioxidants, such as andaliman, have been linked to cancer treatment with few side effects. (Situmorang dan Ilyas, 2018; Wijaya et al., 2019).

ZAM can also be used to reduce apoptosis in cancer cells. Apoptosis disrupts oxidation-phosphorylation and electron transport as a result of radiation and the presence of certain second messengers such as ceramides, as well as changes in cell redox potential and derivatives of Reactive Oxygen Species (ROS) (Thiriet, 2011; Tusskom, 2019). Through signal transduction, DNA damage stimulates the expression of a protein known as p53 and increases intracellular Ca²⁺ ions (Mrakovic dan Fröhlich, 2018). Apoptosis has been linked to increased ROS production and oxidative stress. As a result, apoptosis plays a role in cancer pathogenesis and etiology (Situmorang dan Ilyas, 2018). Because antioxidants have become a widely accepted therapeutic

approach, they have a very close relationship with cancer. Most chemotherapeutic and radiation-killing agents kill tumor cells through an increase in free radicals, which causes irreversible tissue damage, rather than an increase in antioxidants. Appropriate antioxidant inhibitors, such as andaliman, can be used to treat cancer. This herb has the potential to be developed as a candidate for cervical cancer drugs based on histology and a positive index (Figure 4 and Table 4).

CONCLUSION

Giving ZAM had no effect on rat body weight but had a significant effect on cervical cancer weight ($p < 0.05$). Because ZAM contains strong antioxidants, it significantly reduced the expression of MMP-9, GLUT-1, and apoptosis in cancer tissue ($p < 0.01$), making it an effective cancer treatment strategy with molecular therapy.

MMP-9 and GLUT-1 Expression in histology Changes of Cervical Carcinoma as a result of Zanthoxylum acanthopodium

ORIGINALITY REPORT

17%

SIMILARITY INDEX

9%

INTERNET SOURCES

15%

PUBLICATIONS

2%

STUDENT PAPERS

PRIMARY SOURCES

- 1** Rostime Hermayerni Simanullang, Syafruddin Ilyas, Salomo Hutahaeen, Rosidah, Risma Dumiri Manurung, Putri Cahaya Situmorang. "Effect of Andaliman Fruit Extract on Cervical Cancer Rat's Histology", 2021 IEEE International Conference on Health, Instrumentation & Measurement, and Natural Sciences (InHeNce), 2021
Publication 2%
- 2** Putri Cahaya Situmorang, Syafruddin Ilyas, Salomo Hutahaeen, Rosidah Rosidah. "Histological changes in placental rat apoptosis via FasL and Cytochrome c by the nano-herbal Zanthoxylum acanthopodium", Saudi Journal of Biological Sciences, 2021
Publication 2%
- 3** jppres.com
Internet Source 2%
- 4** www.scielo.br
Internet Source 1%

5	hdl.handle.net Internet Source	1%
6	sites.kowsarpub.com Internet Source	1%
7	www.scilit.net Internet Source	1%
8	www.oncotarget.com Internet Source	1%
9	www.ncbi.nlm.nih.gov Internet Source	1%
10	www.coloproctol.org Internet Source	1%
11	Reda El-shaat Mohamed, Magdy M. El-Said, Mohamed M. H. Arief. "Phytochemical Screening of Cinnamon Cassia and Its Protective Effects Against Hepatotoxicity Induced By Difenconazole in Male Albino Rats.", Research Square Platform LLC, 2021 Publication	<1%
12	Elizabeth W. Newcomb. "A Correlative Study of p53 Protein Alteration and p53 Gene Mutation in Glioblastoma Multiforme", Brain Pathology, 7/1993 Publication	<1%
13	www.journaltocs.ac.uk Internet Source	<1%

- | | | |
|----|--|-----|
| 14 | Submitted to University of Greenwich
Student Paper | <1% |
| 15 | Jun Pei, Moudong Wu, Shuyu Cai, Jinpu Peng, Xiong Zhan, Dan Wang, Wei Wang, Nini An. "The Protective Effect of Ursolic Acid on Unilateral Ureteral Obstruction in Rats by Activating the Nrf2/HO-1 Antioxidant Signaling Pathway", Research Square Platform LLC, 2021
Publication | <1% |
| 16 | Leonhard H. Urner, Yasmine B. Maier, Rainer Haag, Kevin Pagel. "Exploring the Potential of Dendritic Oligoglycerol Detergents for Protein Mass Spectrometry", Journal of the American Society for Mass Spectrometry, 2018
Publication | <1% |
| 17 | www.acarindex.com
Internet Source | <1% |
| 18 | Lars Edvinsson, Anne-Sofie Grell, Karin Warfvinge. "Expression of the CGRP Family of Neuropeptides and their Receptors in the Trigeminal Ganglion", Journal of Molecular Neuroscience, 2020
Publication | <1% |
| 19 | Wendy S. Smith, David A. Johnston, Harrison J. Wensley, Suzanne E. Holmes, Sopsamorn U. Flavell, David J. Flavell. "The Role of | <1% |

Cholesterol on Triterpenoid Saponin-Induced Endolysosomal Escape of a Saporin-Based Immunotoxin", International Journal of Molecular Sciences, 2020

Publication

20

www.tandfonline.com

Internet Source

<1%

21

"Abstracts", Fundamental & clinical Pharmacology, 6/2008

Publication

<1%

22

apps.dtic.mil

Internet Source

<1%

Exclude quotes Off

Exclude matches Off

Exclude bibliography Off